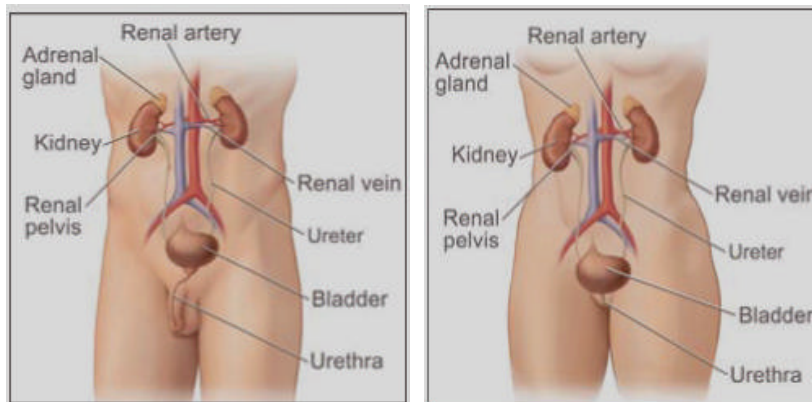


KIDNEY (RENAL CELL) CANCER

KIDNEY (RENAL CELL) CANCER

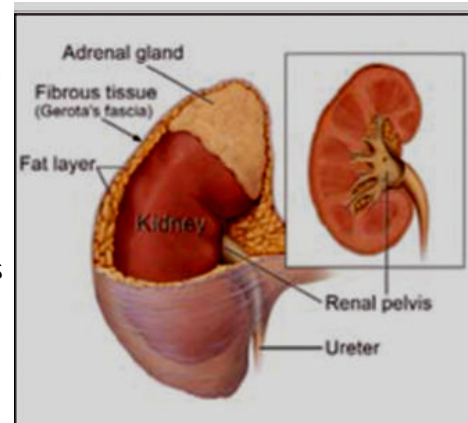
Anatomy

The kidneys are a pair of organs located in the mid-back on either side of the backbone. The lower ribs form a cage around the kidneys. A tough layer of tissue called Gerota's fascia surrounds the kidneys and acts as a protective barrier. The job of the kidneys is to filter excess water and waste products from the blood. The water and waste drain from each kidney through a tube called a ureter into the bladder and are eliminated from the body as urine. The kidneys also produce substances that help control blood pressure and formation of red blood cells.



Epidemiology

In 2008, 54,390 people in the United States were diagnosed with kidney cancer. Most of these cases occurred in people aged 50-70 years, but the disease can occur at any age. About twice as many men develop this cancer as compared to women, and it occurs in all races and ethnic groups. The most common form of kidney cancer is renal cell carcinoma (RCC). The incidence of RCC has risen steadily each year during the last three decades in most of the world, with an average increase of 2% to 3% per year. Most renal masses are now discovered incidentally during imaging prompted by non-specific or unrelated symptoms.



Risk Factors

Most people who have the following risk factors do not get kidney cancer, in fact, most people who are diagnosed with the disease have no known risk factors at all.

- **Smoking:** Cigarette smoking is a major risk factor. Cigarette smokers are twice as likely as nonsmokers to develop kidney cancer. Cigar smoking also may increase the risk of this disease.
- **Obesity:** People who are obese have an increased risk of kidney cancer.
- **High blood pressure:** High blood pressure increases the risk of kidney cancer.
- **Long-term dialysis:** Dialysis is a treatment for people whose kidneys do not work well. It removes wastes from the blood. Being on dialysis for many years is a risk factor for kidney cancer.

- Von Hippel-Lindau (VHL) Syndrome: VHL is a rare disease that runs in some families. It is caused by changes in the VHL gene. An abnormal VHL gene increases the risk of kidney cancer. It also can cause cysts or tumors in the eyes, brain, and other parts of the body. Family members of those with this syndrome can have a test to check for the abnormal VHL gene. For people with the abnormal VHL gene, doctors may suggest ways to improve the detection of kidney cancer and other diseases before symptoms develop.
- Gender: Males are more likely than females to be diagnosed with kidney cancer. Each year in the United States, about 20,000 men and 12,000 women learn they have kidney cancer.

Symptoms

In a study in the Journal of Urology, approximately 53% of people with localized renal cell carcinoma had no symptoms. Symptoms may occur only when the cancer grows and begins to press on surrounding tissues or spread to other parts of the body. The symptoms vary considerably from person to person. Some people never develop any symptoms; the cancer is found when they undergo imaging tests, such as a CT Scan, for another reason.

Symptoms of renal cell cancer may include the following:

- Hematuria (blood in the urine)
- Pain in the flank (side or back above the waist) that will not go away
- Noticeable mass (lump) in the flank
- Weight loss
- Fatigue (feeling tired)
- Loss of appetite
- Fevers
- Night sweats
- Malaise (feeling "blah")

Renal cell cancer has been described as the "Internist's tumor," as it can also cause a number of conditions called paraneoplastic (cancer associated) syndromes. These may be found during routine blood testing or physical exam and can lead your internist to look for a renal mass. Some of the syndromes include:

- High blood pressure
- Hypercalcemia (high level of calcium in the blood)
- Polycythemia (abnormally high number of red blood cells)
- Liver disorders/elevated liver function tests also called Stouffer's syndrome
- Muscle weakness
- Neuropathy (numbness, tingling or burning pain in one or more areas)
- Amyloidosis (abnormal protein deposition in the body)

Diagnosis

If renal cell cancer is suspected, a series of examinations, procedures, and laboratory tests may be performed to confirm the diagnosis. A thorough physical examination is completed to assess the patient's health and obtain information about symptoms and medical history. Laboratory tests include a urinalysis, a complete blood count and a full chemistry panel. One or more imaging tests may be performed. A renal ultrasound may also be of benefit in evaluating the kidney but does not fully assess the remainder of the abdomen. A computed tomography scan (CT scan) can detect tumors and, if present, lymph nodes that may harbor cancer. A CT scan needs to be performed without and with IV (intravenous) contrast in the same setting. Magnetic resonance imaging (MRI scan) may be necessary if the diagnosis is equivocal on the CT scan or if more information is needed. In some cases, the physician may request a venacava-gram to evaluate the main blood vessel that drains the kidneys to look for tumor growing into the veins. A standard chest x-ray may be used to detect spread

(metastasis) to the lungs, and a bone scan (a nuclear imaging procedure) is used to detect possible spread to the bones. Urologists usually avoid obtaining needle biopsies because of the fact that a negative needle biopsy does not necessarily rule out malignancy and since a majority of renal masses consistent with renal cell cancer follow a distinct appearance on imaging.

Staging

The grade of a cancer cell is an assessment of its appearance compared to that of a normal, healthy cell. Grading gives information regarding the inherent aggressiveness of the cells causing the cancer and is used in conjunction with staging to determine the long-term outcome. Grading for renal cell cancer is done on a scale of 1 to 4: Grade 1 cells differ little from normal kidney cells, typically spread slowly, and have a good prognosis for treatment. Grade 4 cells look extremely different and indicate an aggressive cancer with poor prognosis.

The following staging system, referred to as the TNM system, is most commonly used.

Primary Tumor (T); all sizes measured in greatest dimension:

- TX Primary tumor cannot be assessed
- T0 No evidence of primary tumor
- T1 Tumor 7 centimeters (cm) or less, limited to the kidney
- T2 Tumor more than 7 cm, limited to the kidney
- T3 Tumor extends into major veins or invades the adrenal gland or surrounding tissue, but not beyond the Gerota's fascia (the fibrous tissue surrounding the kidney that separates it from adjacent musculature)
- T3a Tumor invades the adrenal gland or surrounding tissue, but not beyond the Gerota's fascia
- T3b Tumor grossly extends into the renal vein or veins (the main blood vessels that carry blood from the kidney) or the vena cava (the large vein that drains blood back to the heart)
- T4 Tumor invades beyond the Gerota's fascia

Regional Lymph Nodes (N):

- NX Regional lymph nodes cannot be assessed
- N0 No regional node metastasis
- N1 Metastasis in a single regional lymph node
- N2 Metastasis in more than one regional lymph node

Distant Metastasis (M):

- MX Presence of metastasis cannot be assessed
- M0 No distant metastasis present
- M1 Distant metastasis present

Treatment

Once a diagnosis of renal cell cancer has been confirmed, it is important that the patient and physician make an informed decision regarding treatment together after considering all possible options, side effects, and outcomes. Unfortunately, renal cell cancer poorly responds to chemotherapy and radiation therapy, thus making definitive local treatment the only option for curative intent.

Patients diagnosed with a small renal mass with radiologic characteristics consistent with RCC may be candidates for active surveillance (AS) with delayed or, alternatively, no treatment rendered. Indications for AS include elderly patients, those with decreased life expectancy or those with medical comorbidities (other medical problems) that would be associated with increased risk if a therapeutic intervention were to be undertaken. A judicious period of AS appears to be associated with a low risk of size or stage progression while maintaining most therapeutic options.

Surgical intervention has been the mainstay for management of clinically localized renal cell cancer. Even within surgery, many options exist. The kidney and the surrounding tissue can be removed in its entirety. This can be performed through an open incision in the flank or upper abdomen and is referred to as an open radical nephrectomy. Similarly, depending upon the tumor characteristics and patient history, the tumor itself may be removed from the kidney in a surgery called open partial nephrectomy. Fortunately, advancements in surgery permit these procedures to be performed less invasively by utilizing cameras, thus allowing smaller incisions, less pain and shorter hospital stays.

These surgeries are called laparoscopic or robotic radical nephrectomy and laparoscopic or robotic partial nephrectomy, respectively. The literature includes many reports of the advantages of these approaches with virtually unanimous agreement that there is reduced perioperative and postoperative morbidity while maintaining equivalent short- and long-term oncologic efficacy.

Again, depending upon tumor characteristics and patient health, other localized treatment options exist. Renal ablative techniques were developed in an effort to improve patient procedural tolerance and reduce the potential for complications. Energy-based tissue-ablative techniques include radiofrequency ablation (RFA) and cryoablation. Controversy exists about which technology is superior. Renal tumor ablations can be performed through open incisions or via laparoscopic or percutaneous (probes passed through the skin) routes under image guidance. While it is likely that outcomes associated with ablative modalities will improve with further advances in technology and application, judicious patient selection remains of paramount importance.

In the setting of advanced disease where local treatment is not curative, medical oncology treatment protocols are utilized. Unfortunately, renal cell cancer has proven to be particularly resistant to chemotherapy and radiation therapy. Research to develop more effective chemotherapy drugs is ongoing. Drugs approved by the FDA to treat advanced renal cell cancer include sorafenib (Nexavar®), sunitinib (Sutent®), and temsirolimus (Torisel™). These drugs may slow disease progression and increase survival time in some patients.

Surveillance

Surveillance includes routine imaging of the abdomen with a CT scans and the chest with plain x-rays along with blood tests. The timing is dependant upon the stage and grade of the tumor.

Prevention

Tobacco use and obesity are the most consistently identified risk factors for RCC, accounting for about 20% and 30% of cases, respectively. Smoking cessation along with moderate alcohol, fruit, vegetable and fatty fish consumption have been reported to reduce the risk of renal cell cancer development.